



Residual Ridge Under Long Standing Bridge

Series A, Number 5

JOHN LUPOVICI, DDS. *New York, New York*

Presentation

A 47-year-old patient presented with a request for implant placement in the site of #9, long standing Maryland Bridge. The site was lacking ridge width to support implant placement.

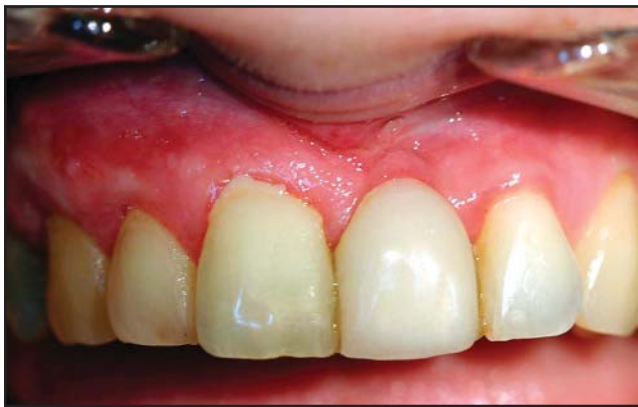

FIG. 1: Pre-treatment view of existing restoration.

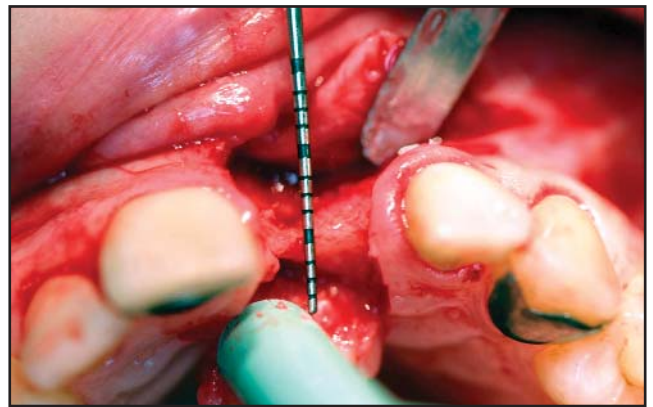


FIG. 2: Exposure of ridge defect, showing as little as 1mm ridge thickness on the mesial aspect of implant site.

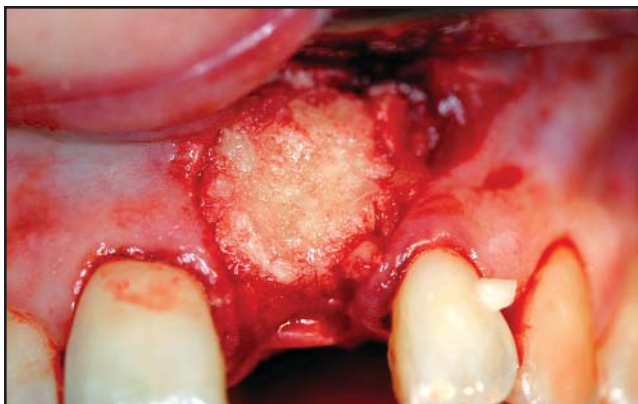


FIG. 3: Placement of 0.5cc Regenaform® in prepared graft site. The area was lightly decorticated and cleaned of all tissue tags and remnants prior to placement.

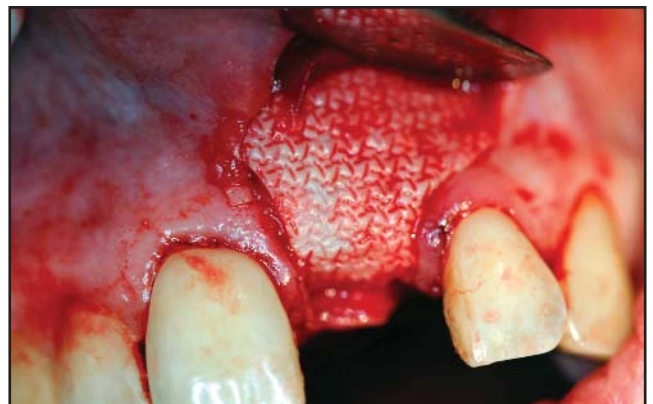

FIG. 4: Ossix® collagen membrane placement

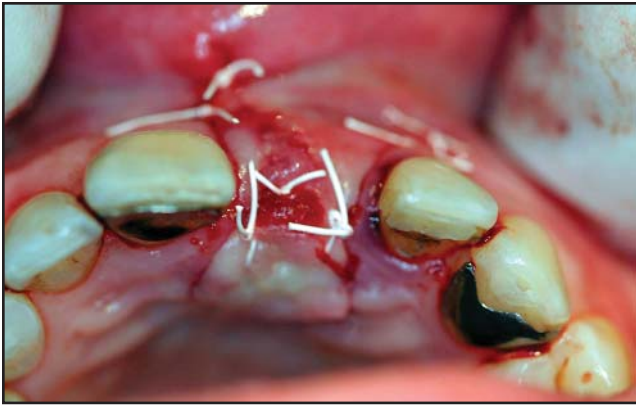

FIG. 5: Flap closure with non-resorbable Gore-Tex® 4.0 suture.

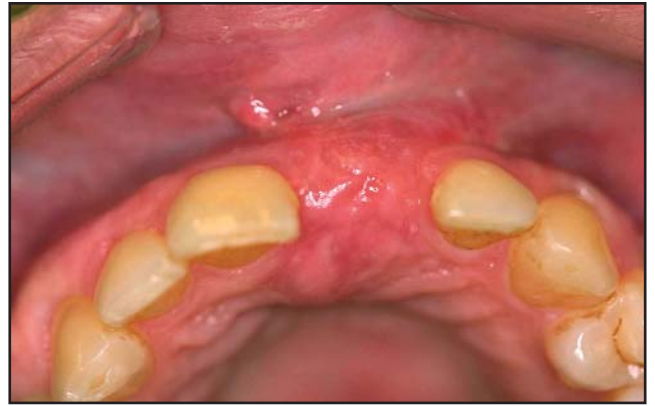

FIG. 6: 4 1/2 month pre-re-entry of site.

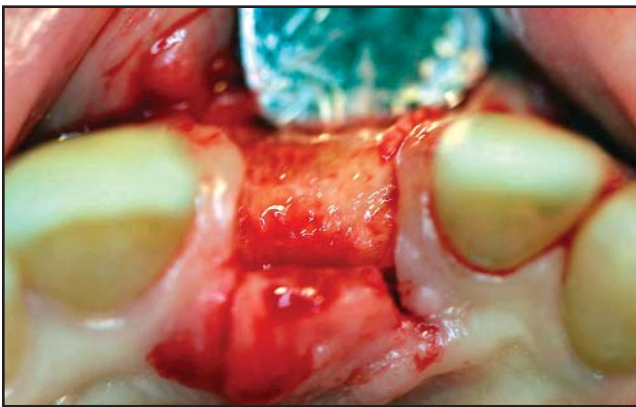


FIG. 7: 4 1/2 month exposure of ridge.

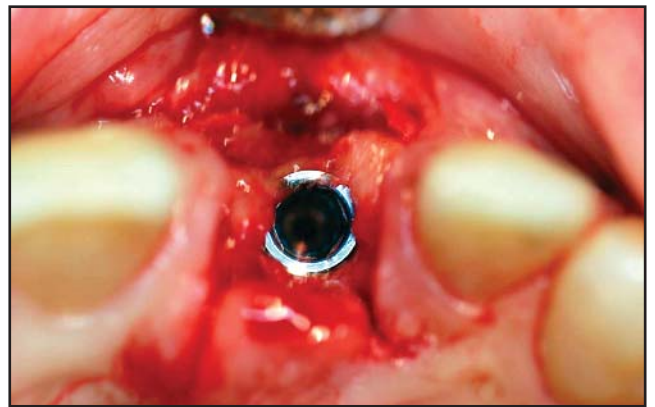


FIG. 8: 4mm Certain® implant fixture placement post-op.

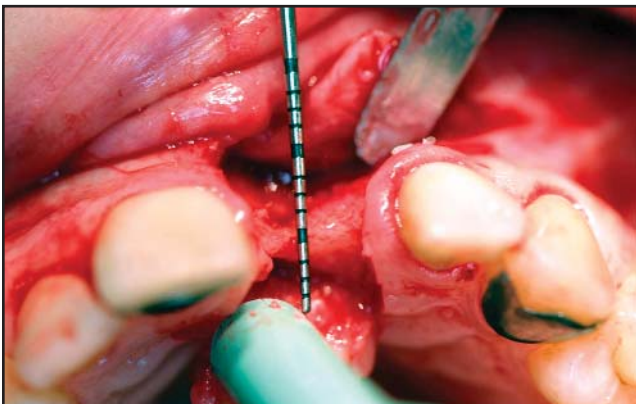


FIG. 9: Pre-op.

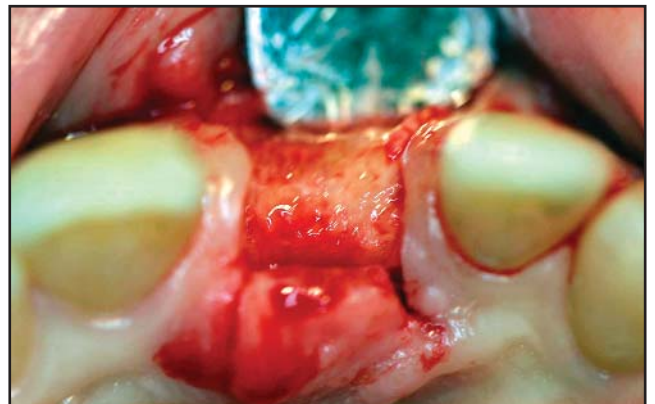


FIG. 10: Post-op 4 1/2 months.

Exactech®

2320 NW 66th Court
Gainesville, Florida 32653
1-866-284-9690 www.exac.com

Ossix® and Certain® implant system are registered trademarks of 3i Implant Innovations, Inc. Gore-Tex® is the registered trademark of W.L. Gore & Associates, Inc.

©2005 Exactech, Inc.
717-00-64 0805